



Rohrmann Endowment for UW Radiology Resident Educational Excellence

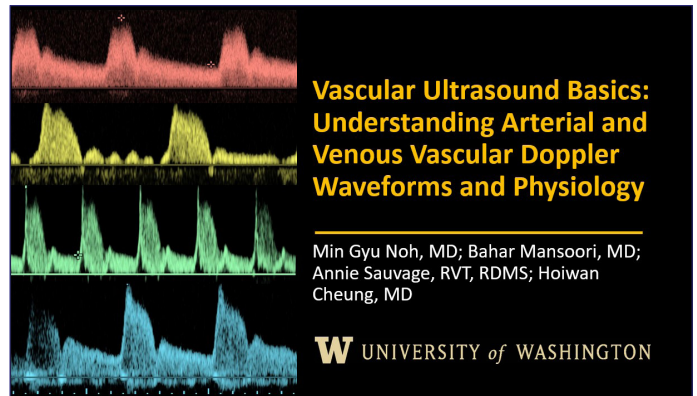
Rohrmann Endowment supports residents' RSNA 2022 experience!

The UW Rohrmann Endowment for Radiology Resident Educational Excellence funds support residents whose first-author educational and scientific exhibits are accepted for presentation at national radiological society meetings. The RSNA 2022 annual meeting was an excellent opportunity for UW Radiology residents to showcase their excellent work. UW Radiology residents and their mentors received many honors at this year's meeting.

Certificate of Merit

Min Gyu "Russell" Noh, MD, PGY-3 and his co-authors were awarded the **Certificate of Merit** for their educational exhibit, "Vascular Ultrasound Basics: Understanding Arterial and Venous Vascular Doppler Waveforms and Physiology."

Russell's travel expenses were funded by the **Rohrmann Endowment**. Many thanks to our generous donors whose contributions make this funding possible!



Vascular Ultrasound Basics: Understanding Arterial and Venous Vascular Doppler Waveforms and Physiology

Min Gyu Noh, MD; Bahar Mansoori, MD; Annie Sauvage, RVT, RDMS; Hoiwan Cheung, MD

W UNIVERSITY of WASHINGTON

Lose the Battle and Win the War: Multimodality Imaging of Diseases Unique to Immunosuppressed

Pegah Khoshpouri, MD¹; Jonathan Revels, DO²; Jennifer Huang, MD, MEd³; Parisa Khoshpouri, MD⁴; Thomas Eggert, MD⁵; Ayman Gaballah, MD⁶; Mariam Moshiri, MD⁶

¹University of Washington, Seattle, WA
²New York University Langone Health, NY
³Vanderbilt University Medical Center, Nashville, TN
⁴Johns Hopkins University, Baltimore, MD
⁵University of Missouri, Columbia, MO
⁶Vanderbilt University Medical Center, Brentwood, TN



Disclosures:
Mariam Moshiri: RSNA Case collection editor
Remaining authors report no relevant disclosures



UW Medicine

Certificate of Merit

Certificate of Merit award-winning exhibit, with Pegah Khoshpouri, MD, PGY-3 as first author: "Lose The Battle and Win the War: Multimodality Imaging of Diseases Unique to Immuno-Suppressed"

"It has always been exciting for me to work on educational projects, especially since I started my residency and was introduced to the limitless nature of Radiology. I am so obliged for the opportunity to take the lead on two exciting educational exhibits for RSNA 2022, one of which was awarded a **Certificate of Merit** and the other one which was solicited by **RadioGraphics**. Furthermore, it was an inexpressible joy to attend the RSNA 2022 in person, see my former and current mentors, colleagues, and friends, and learn from amazing teachers and leaders in the field.

My special thanks go to the **Rohrmann Endowment** for the financial support. Importantly, I want to give my thanks and gratitude to Dr. Mariam Moshiri for her mentorship along the way, as well as Parisa Khoshpouri, a postdoc fellow and my sister, for her incredible contribution, and my senior resident and now a neuro fellow, Thomas Eggert, for sharing amazing cases."

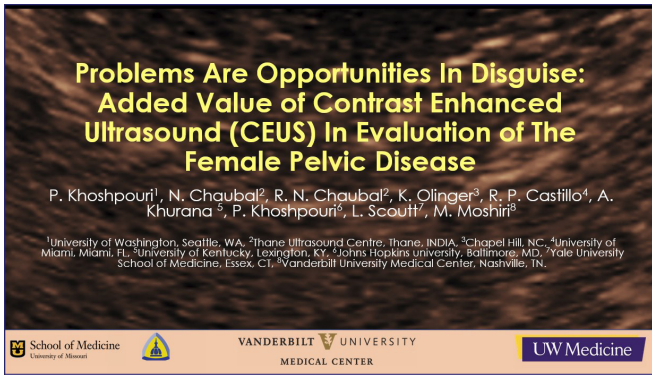– Pegah Khoshpouri, MD, PGY-3

You can support UW Radiology Resident Educational Excellence!

Donating to the Department of Radiology is crucial to carrying out our mission to train the practitioners and leaders of tomorrow, Learn about the many ways to support our department:

<https://rad.washington.edu/donate/>

More Awards from RSNA 2022!



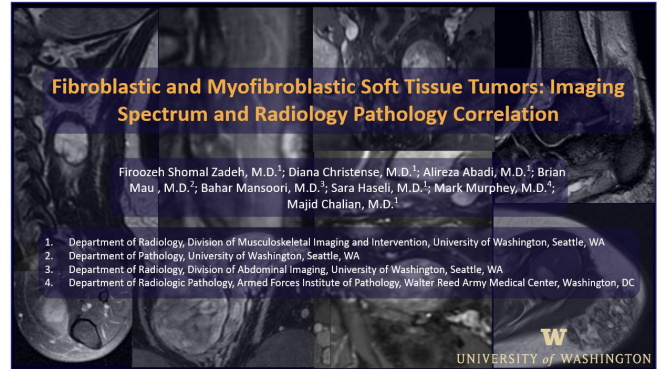
Identified for RadioGraphics

In addition to the **Certificate of Merit** award for her first-author exhibit on Multimodality Imaging of Diseases Unique to Immuno-Suppressed (see p. 1), **Pegah Khoshpouri, MD, PGY-3** and her co-authors were awarded **Identified for RadioGraphics** for this exhibit: *“Problems are Opportunities in Disguise: Added Value of Contrast Enhanced Ultrasound (CEUS) in Evaluation of the Female Pelvic Disease”*



Certificate of Merit Identified for RadioGraphics

“Fibroblastic and Myofibroblastic Soft Tissue Tumors: Imaging Spectrum and Radiology Pathology Correlation” was awarded both the **Certificate of Merit** award and **Identified for RadioGraphics**, by **Firoozeh Shomal Zadeh, MD, Diana Christensen, MD, PGY-3, Alireza Abadi, MD, PGY-5, Bahar Mansoori, MD, Sara Haseli, MD, Mark Murphy, MD, and Majid Chalian, MD**



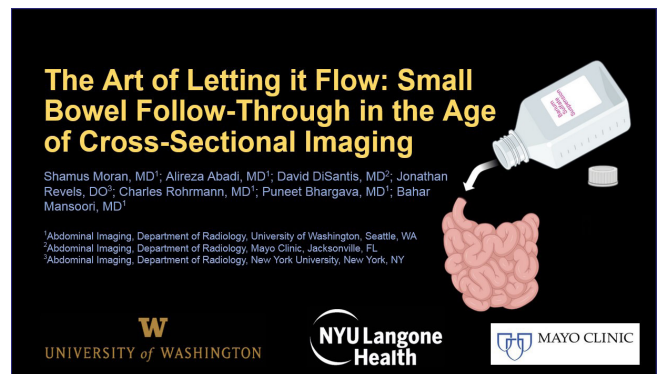“This exhibit on fibroblastic and myofibroblastic soft tissue tumors was a collaborative project to develop a comprehensive review of the typical imaging, pathologic, and clinical features of a heterogeneous group of mesenchymal tumors occurring throughout the body in both children and adults. My role in this project predominantly involved literature review and manuscript preparation. With our upcoming manuscript in [RadioGraphics](#), we hope to provide an educational resource for radiologists on this important group of neoplasms so they may provide accurate radiologic assessments and differential diagnoses and contribute to the appropriate clinical management of these lesions.”

– *Diana Christensen, MD, PGY-3*



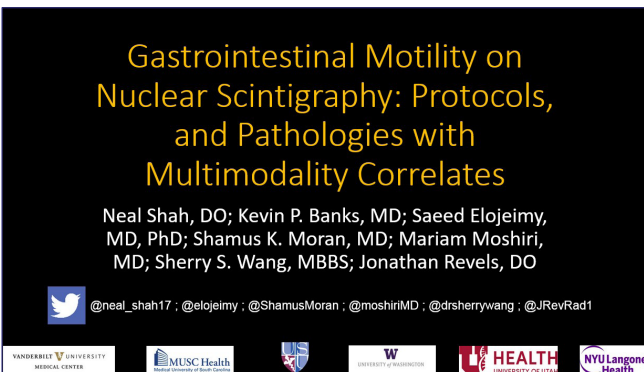
Identified for RadioGraphics

First author **Shamus Moran, MD, UW Radiology Acting Instructor (Cancer Imaging)** and second author **Alireza Abadi, MD, PGY-5**, along with UW Radiology faculty **Charles Rohrmann, MD, Professor Emeritus, Puneet Bhargava, MD, Professor, and Bahar Mansoori, MD, Assistant Professor**, received an **Identified for Radiographics** award for their exhibit: *“The Art of Letting it Flow: Small Bowel Follow-Through in the Age of Cross-Sectional Imaging”*



Certificate of Merit Identified for RadioGraphics

Contributing author **Shamus Moran, MD, UW Radiology Acting Instructor (Cancer Imaging)**: *“Gastrointestinal Motility on Nuclear Scintigraphy: Protocols, and Pathologies with Multimodality Correlates”* Shamus received funding from the [Michael and Rebecca McGoodwin Endowment for Radiology Resident and Fellow Training and Education](#) for his travel to the RSNA 2022 annual meeting.




Your Endowment Support Makes a Difference!

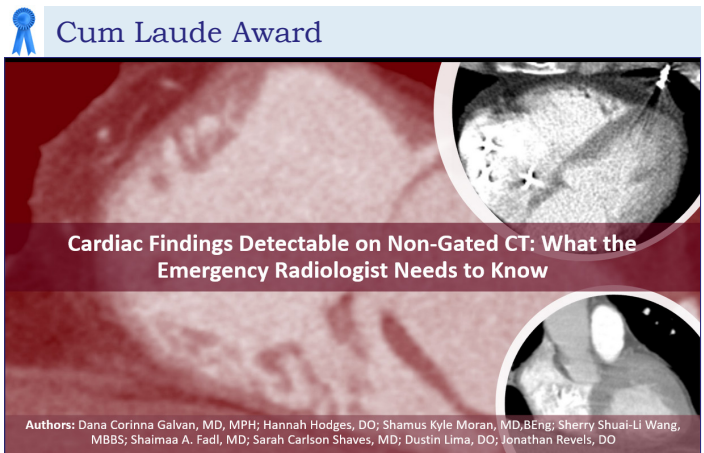“I am forever grateful to the **Michael and Rebecca McGoodwin Endowed Fund for Radiology Resident and Fellow Training and Education** for sponsoring my attendance at the RSNA annual meeting. As a sophomore attendee, I had an understanding of the pitfalls of trying to attend all interesting sessions listed in the day’s schedule. This year, I planned each day ahead of time to maximize high yield sessions, while building in breaks to meet with peers and mentors. Sometimes the most valuable programming is not listed in the meeting agenda but rather created by one-on-one interactions. By happenstance, I was able to connect in-person for the first time with some of the radiologists who had been my co-authors on education exhibits or contributed images to presentations. I was encouraged to reach out for future collaborations or career planning.

The networking opportunities at RSNA are second to none for both trainees and practicing radiologists. Where else do tens of thousands of radiologists from around the world along with industry partners gather for a week? I encourage my trainee colleagues who haven’t had an opportunity to attend to start thinking about possible education exhibits for RSNA 2023. The abstract submission deadline will be here before we know it!”

– Shamus Moran, MD
UW Radiology Acting Instructor (Cancer Imaging)



Richa Patel (left), Shamus Moran (center), and Janis Yee (right), UW Radiology class of '22, reconnect at the RSNA main placard



Authors: Dana Corinna Galvan, MD, MPH; Hannah Hodges, DO; Shamus Kyle Moran, MD, BEng; Sherry Shuai-Li Wang, MBBS; Shaimaa A. Fadl, MD; Sarah Carlson Shaves, MD; Dustin Lima, DO; Jonathan Revels, DO



Jonathan Revels (UW Abdominal and Cardiothoracic Imaging Fellow Alumnus) at the speaker’s podium during his talk on “Infection Induced Cardiothoracic Malignancies.”



Pictured left to right: Janis Yee (UW '22), Shamus Moran (UW Cancer Imaging Fellow '22-23), Richa Patel (UW '22), Russell Noh (UW '25), and Pegah Khoshpouri (UW '25) pose for a group photo after connecting with peers and radiology leaders at the RSNA trainee reception

AN INTERVIEW WITH UW RADIOLOGY ALUMNUS MAHESH THAPA, MD



ALUM SPOTLIGHT



Mahesh Thapa, MD, MEd,
FAAP

Our featured guest interviewee is Dr. Mahesh Thapa, Class of 2005. After graduating from the Diagnostic Radiology Residency at the University of Washington, Dr. Thapa completed his fellowship in Pediatric Radiology at Seattle Children's Hospital and additional training in Musculoskeletal Imaging at the University of Washington.

Dr. Thapa then joined the UW Radiology faculty and rose through the ranks to becoming Professor in 2021. He currently serves as Division Chief of Diagnostic Imaging and Director of Musculoskeletal Imaging at Seattle Children's Hospital. Dr. Thapa has authored over 100 peer reviewed publications on subjects in Pediatric Musculoskeletal Imaging and Radiology Education. Dr. Thapa has also given over 150 invited national and international lectures and been visiting professor at more than 20 prestigious institutions. He is past President of the Alliance of Clinician-Educators in Radiology (ACER), and was awarded the ACER Achievement Award in 2017 for his many contributions to radiology education. In 2019, The Society of Pediatric Radiology presented Dr. Thapa with the Jack O. Haller-Thomas L. Slovis Award for Excellence in Pediatric Radiology Education, their highest honor for educators. Dr. Thapa has kindly shared some of his favorite photographs for your enjoyment!

Where are you from originally?

I was born in Dharan, Nepal. When I was 8 years old, I moved to Las Vegas, Nevada with my aunt and uncle. I attended elementary, middle, high school, and college in Las Vegas. I then went to Los Angeles for medical school before finally arriving in Seattle.

What was your path towards becoming a radiologist?

In medical school, I had a chance to rotate through the Radiology Department. I fell in love with the idea of being able to help so many people in a set amount of time. Rotating through other specialties, I noticed that clinicians were able to see three or four patients per hour. However, in one hour, a radiologist was able to interpret a significantly greater number of exams, and help so many more patients and other doctors.

It was also in medical school that my passion for digital photography was born. I enjoyed the similarities between medical imaging and digital photography.

What was your experience like as a resident at UW Medicine?

I am so incredibly grateful for my experience as a resident at UW Medicine. One of my fondest memories is reading out with Dr. Godwin, where I learned not only to interpret chest radiographs but also how to dictate studies in a succinct, clinically helpful, and relevant manner. I enjoyed the diversity of patient population, the brilliance of the attending physicians, and the empathy everyone shared. It



Wanaka, New Zealand

was in Harborview Medical Center ER where I learned to help care for critically ill patients and gained confidence in my ability to thrive as a solo radiologist. Finally, it was in Roosevelt MSK and Seattle Children's that I honed my skills as a Pediatric Musculoskeletal Radiologist.

What excites you most about radiology and what are some of your specialty areas?

Ever since I can remember, I've loved mystery novels and solving puzzles.

Radiology provides me with countless opportunities to "figure things out" given a brief history and a set of images. I'm constantly playing detective, piecing together clues, and relying on my experience to help answer challenging clinical questions. My areas of expertise include pediatric radiology and pediatric musculoskeletal radiology.

What do you think are some of the most important experiences for residents to have?

I think residents should be exposed to as many of the radiology subspecialties as possible early in their training, because they will have to make decisions about their careers sooner than ever. It is also important for residents to gain confidence about their knowledge base, technical skills, and problem-solving abilities. These come with choosing appropriate mentors, reading as many cases as possible, and taking independent call. Participating in research is also important and will help the residents to think scientifically and encourage them to practice evidence-based medicine.

As Professor of Radiology and Clinical Competency Chair, Pediatric Radiology Fellowship at Seattle Children's Hospital, what is your current role in trainee education, and how would you describe your approach to resident and fellow education?

In a world where every clinician can simply input signs and symptoms into a computer or search engine and come up with a list of possible diagnoses, how does the radiologist fit in? We need to be able to show that we add value by being thoughtful in our differential diagnosis and providing the most likely possibilities instead of a “laundry list.”

I consider my current role as an educator has been similar to what it was when I first started. I try to educate our trainees, faculty, and support staff as best I can, whenever I can. I picture in my mind’s eye, a resident or fellow during her last day of training at Seattle Children’s Hospital. In what way have I affected her life? How is she different from her first day as a trainee? What has she learned from me? My number one hope is that she regards patient care as the most important aspect of her professional life.



Cape Perpetua, Oregon

I also hope I have instilled in her a desire for life-long learning, the humility to accept her limitations, and the fortitude to stand up for her beliefs. I do not see myself as someone to teach her all of pediatric radiology, and I do not see her as a vessel into which knowledge must be poured like a glass of water. Practically, she should have a certain fund of knowledge. However, I want her to know where to turn for answers when faced with issues outside her expertise.

In today’s world with data literally at our fingertips, knowing how and where to obtain reliable information is just as important as the knowledge we carry with us.

What are your areas of research and clinical focus – and some of the biggest challenges you and your colleagues face in Radiology?

My areas of focus are education and pediatric musculoskeletal imaging. I think one of the biggest challenges facing us as radiologists is staying relevant. In a world where every clinician can simply input signs and symptoms into a computer or search engine and come up with a list of possible diagnoses, how does the radiologist fit in? We need to be able to show that we add value by being thoughtful in our differential diagnosis and providing the most likely possibilities instead of a “laundry list.”



Old Man of Storr, Scotland

Radiology is also not immune to physician burnout. We need to establish accommodative work schedules and increase job satisfaction by allowing radiologists to work according to their interests and preferences.

Having great mentors plays such an important role for all of us. Who were some of your early mentors, and your most recent ones?

David Brewer was the pediatric radiologist who made me want to be a pediatric radiologist. His excellent work ethic, inquisitive nature, and calm demeanor were attributes that I strive for even today. Ed Weinberger showed me the proper way to lead through his everyday actions, commitment to faculty/staff, and willingness to try new things. Mike Richardson and Felix Chew were amazing mentors who taught me musculoskeletal radiology and provided countless opportunities at national conferences.



Bandon, Oregon

Follow Mahesh on Instagram [@StarvingPhotographer](#)

(continued on page 6)

Mahesh Thapa: UW Resident Alum & Photographer!

More recently, I've leaned more on my clinical colleagues as mentors. Retired orthopedic surgeon, Vice Mosca, has taught me much about pediatric musculoskeletal issues, providing unique surgical perspectives. His willingness to share has made me a much better pediatric musculoskeletal radiologist. Randy Otto has provided me with leadership opportunities in our department and mentored me through several key interactions.

Finally, I consider my fellow pediatric musculoskeletal radiologists as mentors. They are Ramesh Iyer, Jeff Otjen, Anh Ngo, Sarah Menashe, Helen Kim, and Zeke Maloney. They teach me to remain passionate, share knowledge, and collaborate amicably.

What advice do you give to radiology residents today?

The best advice I can give a radiology resident is the best one I received many, many years ago: choose a sub-specialty based on what you see yourself continuing to do 30 years from now, not based on what the job market is like today.

What are some of your favorite activities outside of work?

I am an avid photographer and hiker.

Fun Facts about Mahesh:

I am also a professional nature photographer and brand ambassador for several photography companies such as Sony, Lowepro, Gitzo, Nisi filters, and B&H Photo and Video. I gained some prominence in photography through social media outlets, mainly Instagram ([@StarvingPhotographer](#)) where I have close to 250K followers.

I love hanging out with Cindy, my wife, and Kishore, our 10-year-old son, watching old TV sitcoms, hiking, and eating grandma's food.



Kishore, Cindy and Mahesh

Rohrmann Endowment funding for educational tools

"With support from the **Rohrmann Endowment** and mentorship from Dr. Bahar Mansoori, Dr. Shamus Moran and I were able to create an educational exhibit for the 2022 RSNA meeting. The project was titled "*The Art of Letting It Flow: Small Bowel Follow-Through in the Age of Cross-Sectional Imaging*" and was subsequently identified to be published by [RadioGraphics Fundamentals](#).

The idea was first inspired by the thorough fluoroscopy curriculum we have at University of Washington. While fluoroscopy is commonly used at UW, at other institutions its use is dwindling as the new generation of radiologists do not have as much experience or comfort with different fluoroscopic exams. Having identified the need, we were able to put together a comprehensive educational exhibit that focused on the basic steps in performing a small bowel follow through, its indications and contraindications, as well as common cases that are likely to be encountered by practitioners.

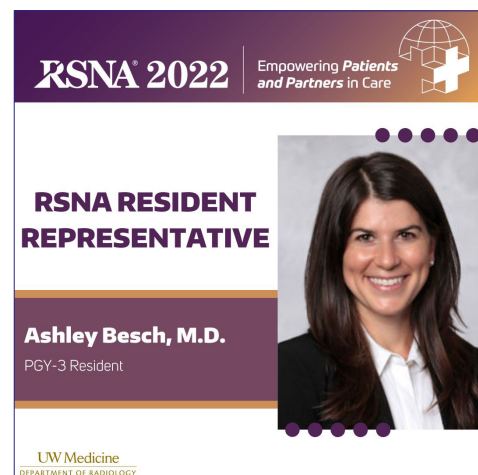I am particularly grateful for the support from the **Rohrmann Endowment** in giving our team access to BioRender, a presentation tool which helped the exhibit be more interactive and intuitive for the audience. As a team, we are thrilled to have the opportunity to continue to work on this project for submission to [RadioGraphics](#)."

– Alireza (Ali) Abadi, MD, PGY-5

RSNA 2022: Resident Representative

"It has been a privilege to be the RSNA Resident Representative for our residency program this year. I have enjoyed highlighting different aspects of the RSNA R3 Newsletter and distributing this information to my co-residents. There are many interesting opportunities, events, awards, and news/research articles that are featured each month. It has been a great experience to be able to share all of this with my colleagues and I hope that many have been able to take advantage of some of these wonderful opportunities!"

– Ashley LW Besch, MD, PGY-3



UW Radiology Reception at RSNA 2022 ... a time to reconnect

This year, more radiologists were able to gather in person at the RSNA 2022 annual meeting in Chicago. Although 2021 offered the opportunity for in-person attendance, we chose to host our annual reception virtually last year. With fewer barriers to travel and a robust interest in returning to in-person events, the UW Radiology Alumni & Friends Reception was held on Tuesday, November 29th at the Sheraton Grand Chicago Riverwalk hotel, in the FountainView Room. This venue provided a beautiful backdrop for UW Radiology alumni to mingle with our faculty and trainees after attending sessions during the day at the convention center.

UW Radiology was pleased to host 60 guests, including many recent resident grads from the Class of 2022 (pictured at right). More photos: [Rohrmann Endowment website](#)

We were also honored with the presence of our former chair, Dr. Norman Beauchamp, who we warmly embrace as part of the UW Radiology family.

This annual reception is open to all UW Radiology alumni, and we hope you can plan to join us next year if you are attending the RSNA annual meeting in Chicago!



Class of 2022 (L to R): Richa Patel, Cody Rissman, Janis Yee, Niketa Kataria, (Guest: Will Carnes), Shamus Moran



L to R: Norman Beauchamp and Dushyant Sahani



Sheraton Grand Chicago Riverwalk, FountainView Room




L to R: Justin Deese, Mahmud Mossa-Basha, Zeinab Abraham, Elliot Rapp, Aaron Rutman



L to R: Domenico Mastrodicasa, Guiseppe Toia, Guilherme Cunha

STAY
CONNECTED!



UwRohrmann

Follow us on social media!



UW Radiology Residency: UW_RadRes
UW IR Residency: UofWa_IR



uw_radres
uofwa_ir



Rohrmann Endowment
UW Medicine, Department of Radiology
1959 NE Pacific St, Box 357115
Seattle, WA 98195

Betty L. Lanman
blanman@uw.edu

Rohrmann Endowment supports Resident Research Publications

RADIOLOGY CASE REPORTS 18 (2023) 519-523

Available online at www.sciencedirect.com
ScienceDirect
journal homepage: www.elsevier.com/locate/radcr

ELSEVIER RCR RADIOLOGY CASE REPORTS

Case Report
Primary thyroid hemangioma, a rare diagnosis in a patient with a painless neck mass[☆]

Joey Seufferling, BS, Alex Diaz, MD^{*}, Neal Futran, MD, DMD, Anshu Bandhlish, MD, Pattana Wangaryattawanich, MD
University of Washington, Main Hospital, 1959 NE Pacific St 2nd Floor, Seattle, WA 98195, USA

“Primary Thyroid Hemangioma, A Rare Diagnosis in a Patient with a Painless Neck Mass”

The aim of this case report was to demonstrate a rare case of primary thyroid hemangioma in a patient who presented with a painless, slowly enlarging neck mass. These lesions are diagnostically challenging, given the lack of specific imaging features and clinical features associated with them. In this case, the patient was treated with right hemithyroidectomy, due to inconclusive FNA results and laboratory work-up which raised concern for a thyroid paraganglioma.

We would like to express thanks and appreciation to the **Rohrmann Endowment** donors for supporting this work. This case report was particularly enjoyable to work on, both due to the interesting nature of this case and the opportunity this work provided to mentor a medical student with an interest in Neuroradiology.

– Alex Diaz, MD, PGY-4

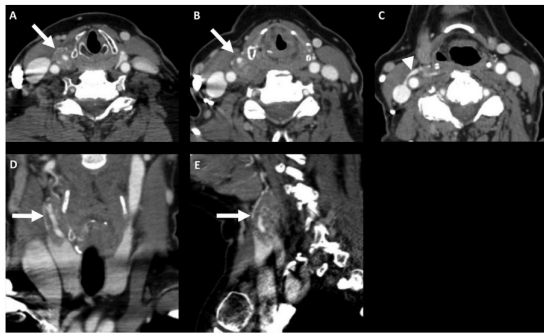

Fig. 1 – Axial (A-C), coronal (D), and sagittal-reformatted (E) contrast-enhanced CT images demonstrate a well-circumscribed, highly vascular, hypodense lesion centered in the superior aspect of the right thyroid gland (arrows) with a prominent vein traversing through the central portion of the lesion and subsequently draining into the right internal jugular vein (arrowhead on C).

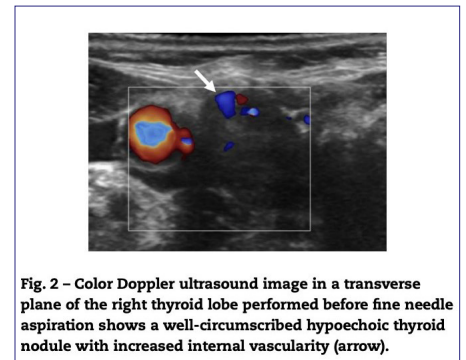



Fig. 2 – Color Doppler ultrasound image in a transverse plane of the right thyroid lobe performed before fine needle aspiration shows a well-circumscribed hypoechoic thyroid nodule with increased internal vascularity (arrow).

See Inside!

Discover the UW Radiology resident alumnus who photographed this spectacular shot of Seattle!




Cityscape, Doctor Jose Rizal Park, Seattle Washington

“The **Rohrmann Endowment** generously funded the publication of our case report “*Oncocytic Carcinoma of the Parotid Gland as a Manifestation of Birt-Hogg-Dube Syndrome*” in the journal *Radiology Case Reports*. This report highlights the first case of parotid oncocytic carcinoma associated with Birt-Hogg-Dube syndrome, with radiologic and histologic correlation.

I would like to express my gratitude to the **Rohrmann Endowment** for providing the opportunity to share our research, and my thanks to mentors Dr. Lei Wu and Dr. Sarah Bastawrous who introduced me to the **Rohrmann Endowment** and made this publication possible.”

– Eric Chen, MD, PGY-3



Eric Chen, MD, PGY-3