

Tumors of the neural crest in children

Which tumors arise from the neural crest?

- Neuroblastoma (malignant)
- Ganglioneuroblastoma (intermediate)
- Ganglioneuroma (benign)
- are a continuous spectrum!
- Definition:
 - Neoplasm arising from either the dorsal root ganglion of the spinal cord or the medulla of the adrenal gland, exhibiting variable degrees of neuroblastic maturation.
- Pheochromocytoma
- Neuroendocrine tumor composed of chromaffin cells most commonly arises from adrenal medulla. About 10% of cases arise from extra-adrenal chromaffin cells.

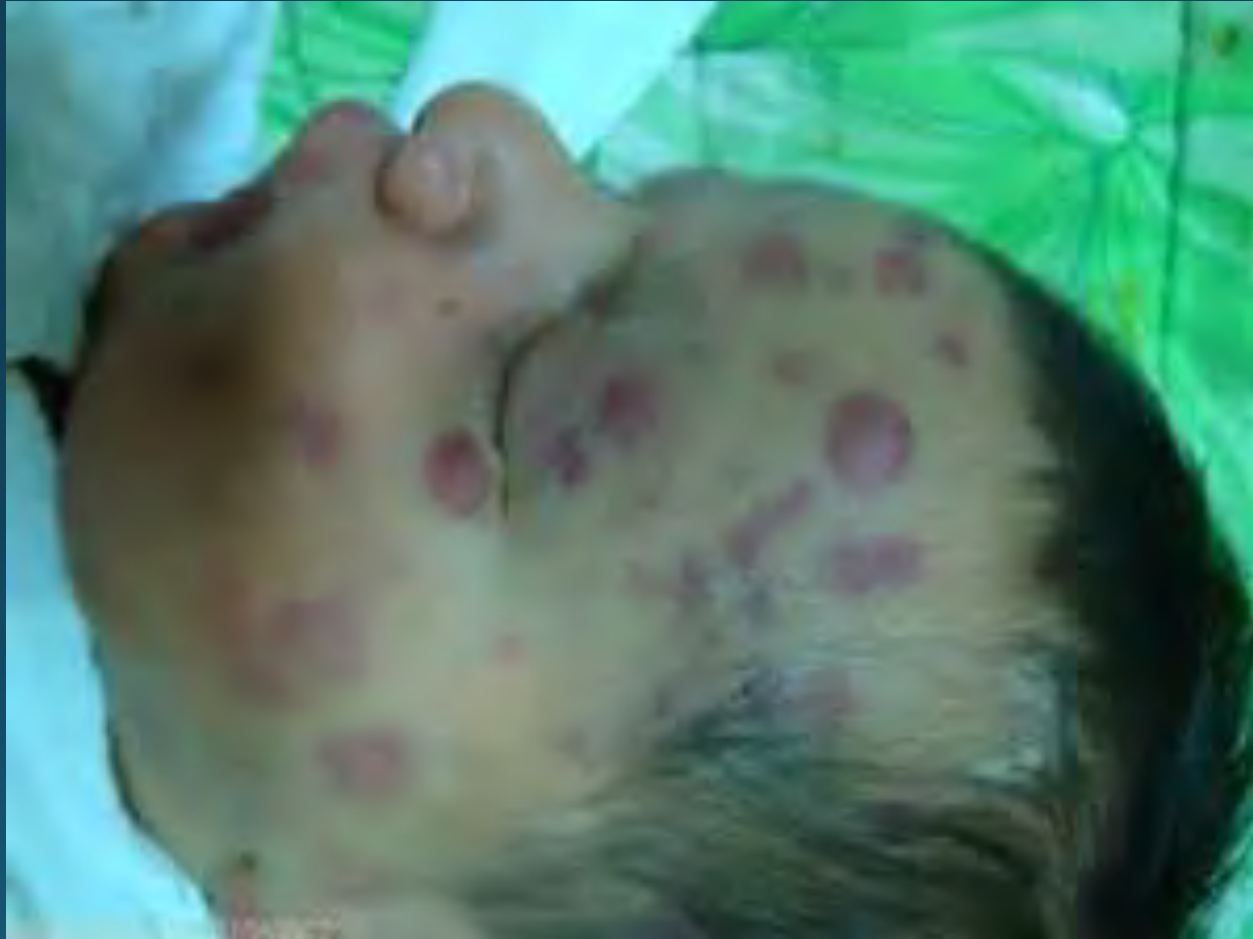Neuroblastoma

- **Epidemiology:** 3rd most common pediatric tumor after leukemia and central nervous system tumors
 - Mean age of presentation is 14 month
- **Fetal neuroblastoma**
 - 90% of cases arise in the adrenal glands. They have been diagnosed as early as 19 weeks of gestation, but usually are seen in the third trimester.
 - Typically tumor undergoes maturation and regression
 - Prognosis is excellent with many institutions recommending conservative management
- **Neonatal neuroblastoma**
 - Much better prognosis than those found in older children with 90% being cured.
 - Only 45% of cases arise from the adrenal glands.
 - In app. 60% of cases metastases are present at the time of diagnosis, mostly to the liver, which may be massively enlarged.

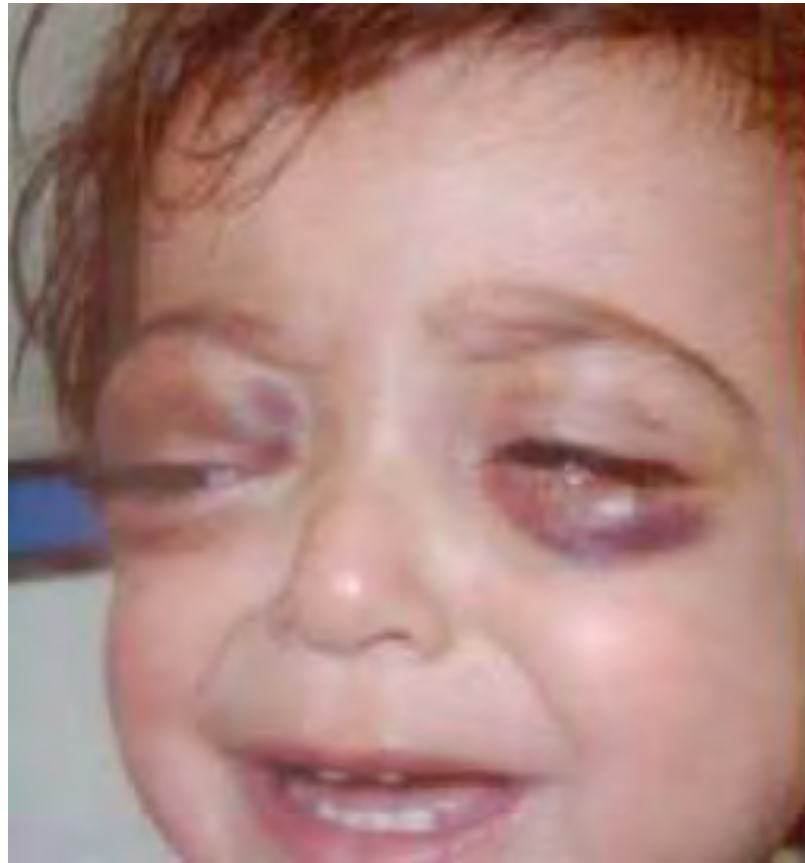Neuroblastoma

- **Clinical presentation**
- Pain or palpable mass and abdominal distension when arising within the abdomen
- Bony metastases may present with skeletal pain or a palpable lump or mass.
- Limping and irritability due to skeletal metastases is known as the Hutchinson syndrome.
- Raccoon eyes (skull base metastasis)
- Blueberry muffin syndrome (skin metastasis)
- Cerebellar ataxia (more common in chest neuroblastoma)
- Hypertension
- Paraneoplastic syndrome opsoclonus-myoclonus (rare)

Blueberry Muffin syndrome



Raccoon eyes



Neuroblastoma

- **Location**
- Neuroblastomas arise from the sympathetic nervous system.
- Most common site of origin:
- Adrenal glands 35%
- Retroperitoneum: 30-35% organ of Zuckerkandl, coeliac axis, paravertebral sympathetic chain
- Posterior mediastinum: 20%
- Neck: 1-5%
- Pelvis: 2-3%

Neuroblastoma

- **Stage 1:** the tumor is in only in one area and all of the tumor that can be seen is completely removed during surgery.
- **Stage 2A:** The tumor is in only one area and all of the tumor that can be seen cannot be completely removed during surgery.
- **Stage 2B:** The tumor is in only one area and all of the tumor that can be seen *may* be completely removed during surgery. Cancer cells are found in the lymph nodes near the tumor.
- **Stage 3,** one of the following is true:
 - The tumor cannot be completely removed during surgery and has spread from one side of the body to the other side and may also have spread to nearby lymph nodes; or
 - The tumor is in only one area, on one side of the body, but has spread to lymph nodes on the other side of the body; or
 - The tumor is in the middle of the body and has spread to tissues or lymph nodes on both sides of the body, and the tumor cannot be removed by surgery.

Neuroblastoma

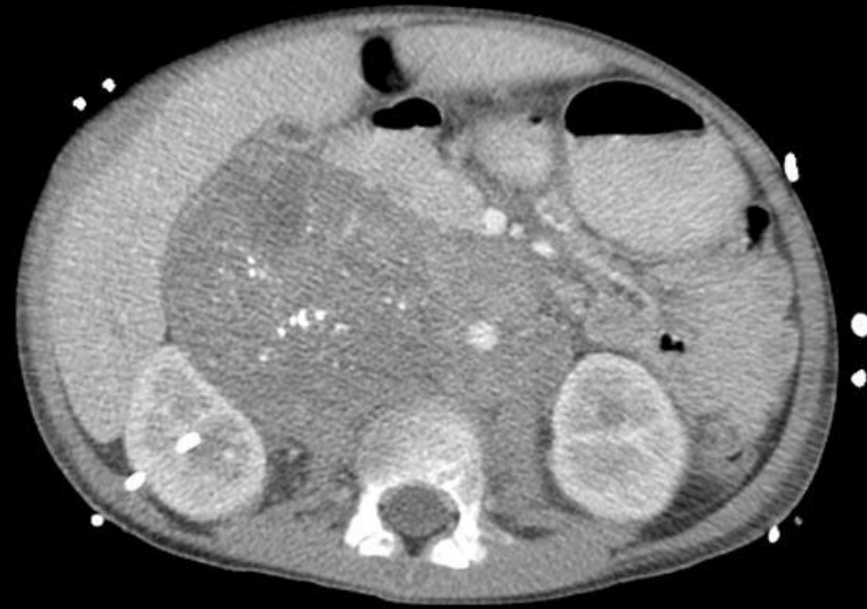
staging continued

- **Stage 4 is divided into stages 4 and 4S**
- In stage 4, the tumor has spread to distant lymph nodes or other parts of the body.
- In stage 4S:
 - the child is younger than 12 months; and
 - the cancer has spread to the skin, liver, and/or bone marrow; and
 - the tumor is in only one area and all of the tumor that can be seen *may* be completely removed during surgery; and/or
 - cancer cells may be found in the lymph nodes near the tumor.

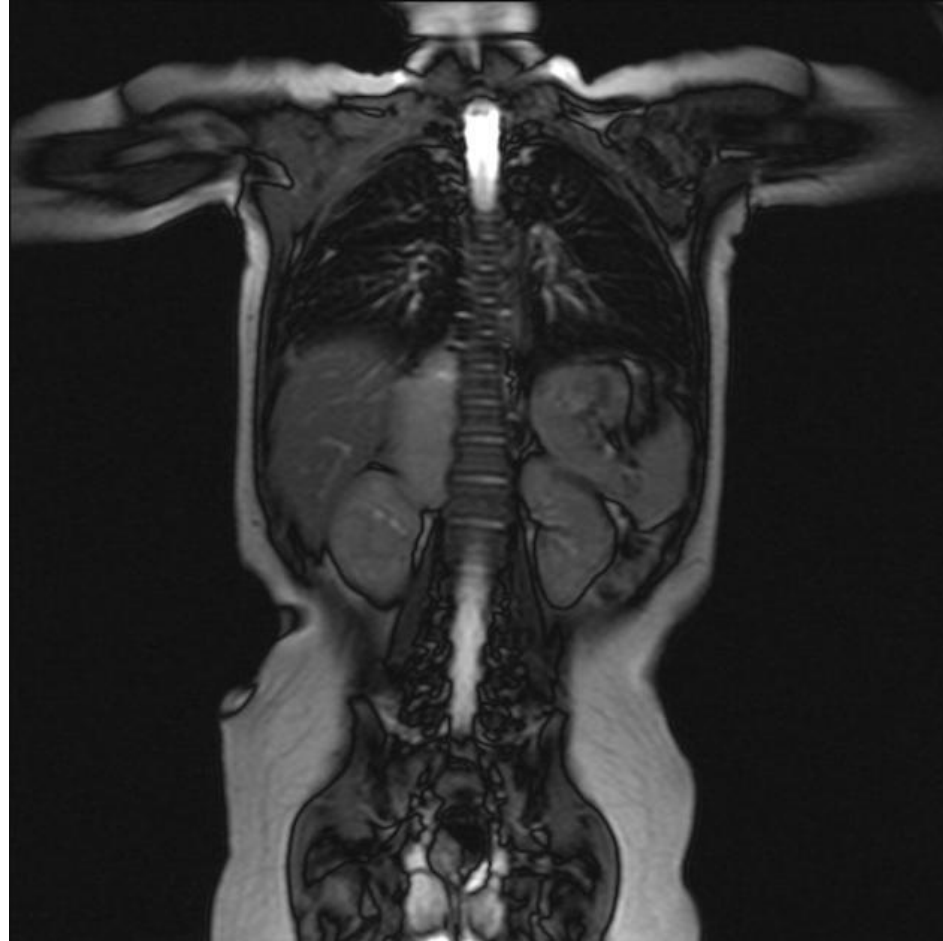
Neuroblastoma

- **Diagnosis:**
- MRI/CT for tumor detection and characterization
- MIBG/SPECT scintigraphy to determine disease extend.
 - 88% sensitivity and 98% specificity in detection of neuroblastoma.
 - Superior to PET/CT in detecting advanced disease and bone marrow metastases.
 - Follow up of disease in MIBG avid tumors (10% are not MIBG avid).
- PET-CT is superior in detecting stage 1 and 2 disease

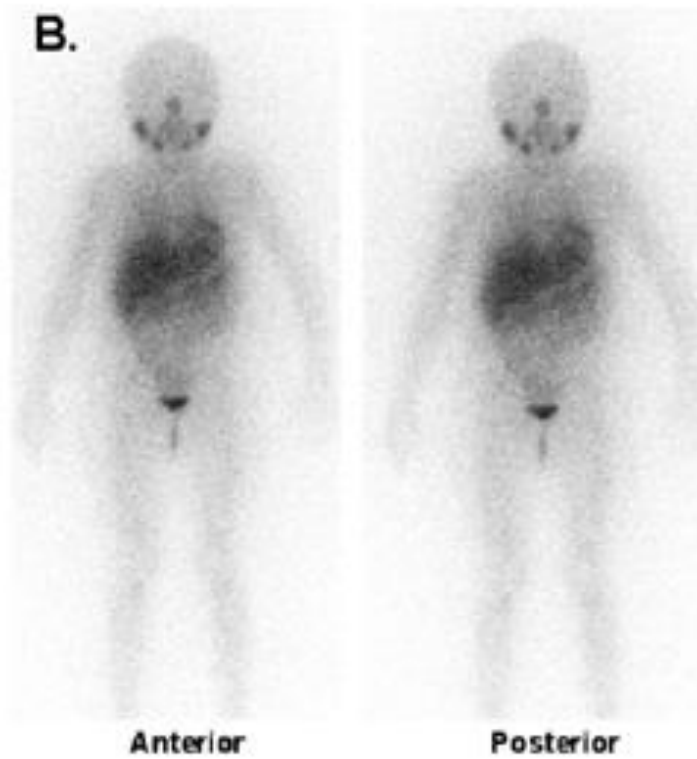
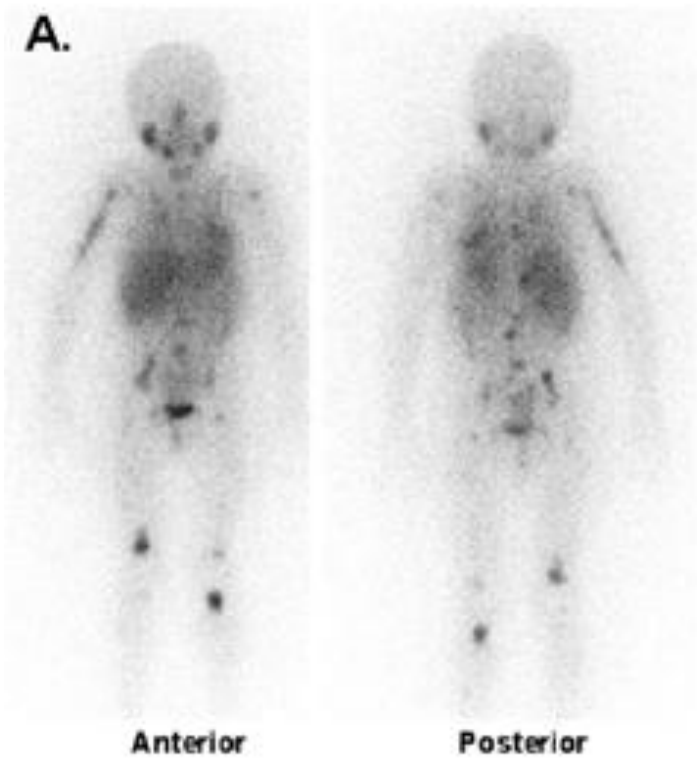
Contrast enhanced CT abdomen



Neuroblastoma coronal MRI TrueFISP



Neuroblastoma MIBG scan



MIBG scintigraphy

- **M**etoiodobenzylguanidine (MIBG) is a norepinephrine analogue
- Active energy dependent amine transport into the cells
- Storage occurs in cytoplasmic storage vesicles in presynaptic adrenergic nerves, adrenal medulla and other adrenergic and neuroblastic tumor tissues.
- Physiological uptake is seen in heart, salivary glands and spleen
- I-131 and I-123 are used as radiolabels
- Imaging occurs 24-48 hrs after injection
- Pt. are given a blocking dose of saturated solution of potassium iodide(SSKI)
- Imaging takes 20 min.
- SPECT is feasible with I-123 radiolabel
- Screen medication for tricyclic antidepressants, reserpine, cocaine, guanethidine, antipsychotics and labetalol

Neuroblastoma

- **Features associated with a better prognosis:**
- Young age of presentation
- Thoracic primary
- Decreased n-MYC amplification
- Stage S₄ : near 100% survival
- **Differential Diagnosis:**
- **Mediastinal mass** in a child < 3 years:
 - no differential diagnosis
- **Abdominal mass:**
- Wilms tumor
- Adrenal hemorrhage (decreased echogenicity on US)
- Pheochromocytoma
- Adrenocortical carcinoma

Neuroblastoma

- Treatment:
 - Depending on stage !!

 - Chemotherapy
 - Surgery
 - Bone marrow transplantation
- MIBG treatment (within clinical trials)

Ganglioneuroma/Ganglioneuroblastom a

- **Common location:**
- Adrenal gland
- Paraspinal retroperitoneum (sympathetic ganglia),
- Posterior mediastinum
- Head
- Neck
- **Ganglioneuroma:**
- Represents the most common posterior mediastinal mass in adolescents and young adults

Ganglioneuroma/Ganglioneuroblastoma

- **Diagnosis:**
- MRI/CT for tumor detection and characterization
- MIBG scintigraphy to determine disease extent.
 - Superior to PET/CT in detecting advanced disease and bone marrow metastases.

Ganglioneuroblastoma:

MIBG scintigraphy: Follow up of disease in MIBG avid tumors (10% are not MIBG avid).

PET/CT in non MIBG avid tumors

Pheochromocytoma

- **Definition:**
- Paraganglioma most commonly arising from the catecholamine producing chromaffin cells of the adrenal medulla. About 10% of cases arise from extra-adrenal chromaffin cells.
- **Associated syndromes:**
- Von Hippel-Lindau syndrome
- Multiple endocrine neoplasia syndrome type 2
- Neurofibromatosis type 1
- **Best diagnostic clue:**
- Suprarenal mass in a child with hypertension

Pheochromocytoma

- **Demographics:**
- Mean age 11 years
- Gender: M:F =2:1
- **Epidemiology:** most common pediatric endocrine tumor
 - Responsible for app. 1% of pediatric hypertension
 - Bilateral tumors in 25-34 %
 - Malignant in 12-56% in pediatric patients (criteria: tumor invasion and distant metastasis)

Pheochromocytoma

- **Clinical presentation:**
- Sustained hypertension
- Symptoms from mass effect
- Headaches, flushing, palpitations, blurred vision, panic attacks, tremor, weight loss
- **Complications:**
- Cardiomyopathy
- Hypertensive crisis
- Cardiovascular accidents
- Seizures

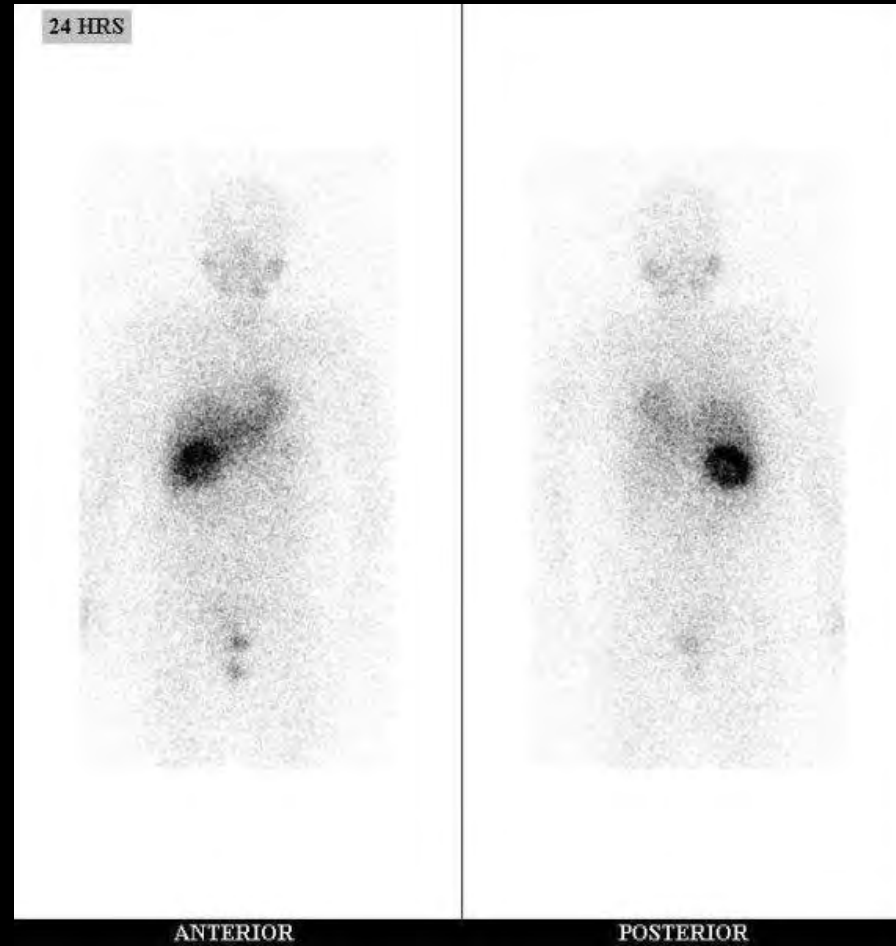
Pheochromocytoma

- **Diagnosis:**
- US/MR
- MIBG scintigraphy: I-123 to look for extraadrenal tumor or metastatic disease
- PET/CT less sensitive and specific to look for extraadrenal tumor or metastatic disease

- **If malignant:** bone, lung and liver metastasis are most common sites

- **Differential diagnosis:**
- Neuroblastoma
- Adrenocortical carcinoma (large adrenal mass that can cause virilization)

Pheochromocytoma



MIBG scan

Pheochromocytoma

- Treatment:
- Surgical excision with beta-blocker pretreatment to block catecholamine effect

Thank you!